



**TissueAid™**

Tratamento de incisão em cirurgia  
toracoscópica: um estudo comparativo  
sobre o TissueAid™ e o método  
tradicional.

Wenjie Huang, M.D.

Director of Thoracic Surgery Department, Mackay Memorial Hospital, Taipei, Taiwan



# TissueAid™

**Objetivo:** O adesivo de tecido 2-octilcianoacrilato tem sido utilizado para muitos fechamentos de feridas cirúrgicas. No entanto, seu uso como dispositivo de fechamento de ferida em cirurgias toracoscópicas vídeo-assistidas não foi avaliado adequadamente. Este estudo de intervenção clínica compara as características dos orifícios de incisão após serem fechados pelo adesivo de tecido TissueAid™ da GeneJet Biotech e aqueles fechados pelo método tradicional em cirurgia toracoscópica vídeo-assistida.

**Método:** 30 pacientes após cirurgias toracoscópicas vídeo-assistidas foram divididos aleatoriamente em dois grupos. As feridas de incisão de 15 pacientes foram tratadas com adesivo de tecido 2-Octilcianoacrilato (TissueAid™), e as dos outros 15 pacientes foram tratadas com sutura de nylon 5-0 padrão. Além do tempo de operação, o Hollander Wound Evaluation Score modificado (WES) e o Visual Analogy Score (VAS) foram utilizados para avaliar a dor pós-operatória, a facilidade de uso, a taxa de complicações, a adesão e a satisfação do paciente. Eles foram avaliados pelos pacientes ou pelos pesquisadores logo após os procedimentos, aos 15 dias e um mês após a cirurgia.

**Resultados:** Os pacientes expressaram uma preferência e satisfação geral pelo adesivo tecidual durante todo o período de avaliação ( $P < 0,05$ ). Da mesma forma, as notas dos pacientes para dor pós-operatória e as notas do investigador para a adesão foram significativamente melhores para o adesivo de tecido em toda a seção de avaliação ( $P < 0,05$ ). Mais pacientes no grupo adesivo tecidual apresentaram nota ótima de avaliação de feridas (WES) do que aqueles no grupo da sutura, duas semanas após a cirurgia. Além disso, o adesivo de tecido é fácil de usar, com um tempo de operação menor que o da sutura.

**Conclusão:** O adesivo de tecido TissueAid™ pode aliviar a dor pós-operatória com melhor efeito estético nas cicatrizes e alcançar maior satisfação do paciente pela incisão causada pelas cirurgias toracoscópicas vídeo-assistidas. O adesivo de tecido TissueAid™ é seguro, eficaz em cirurgias toracoscópicas vídeo-assistidas e uma alternativa consistente para o fechamento de feridas.

# Thoracoscopic Surgery Incision Treatment: A Comparative Study on TissueAid™ and Traditional Method

Wenjie Huang, M.D.

Director of Thoracic Surgery Department, Mackay Memorial Hospital, Taipei, Taiwan

## Abstract:

**Purpose:** 2-Octylcyanoacrylate tissue adhesive has been used for many surgical wound closures. However, its use as port closure device in video-assisted thoracoscopic surgeries has not been properly assessed. This clinical intervention study compares the characteristics of the incision ports after they are closed by GeneJet Biotech's TissueAid™ tissue adhesive and those closed by traditional method in video-assisted thoracoscopic surgery; **Method:** 30 patients after video-assisted thoracoscopic surgeries were randomly divided into two groups. Incision ports of 15 patients were treated by 2-Octylcyanoacrylate tissue adhesive (TissueAid™), and those of the other 15 patients were treated by standard 5-0 nylon suture. Other than the operation time, modified Hollander Wound Evaluation Score (WES) and Visual Analogy Score (VAS) were used to assess the postoperative pain, ease of use, complication rate, wound cosmesis and patient satisfaction. They were assessed either by the patients or by the investigators right after the procedures, at 15th days and one month after surgery.

## Result:

Patients expressed an overall preference and satisfaction for the tissue adhesive throughout the evaluation period ( $P < 0.05$ ). Similarly patients' visual analogue scores for postoperative pain and investigator's visual analogue scores for wound cosmesis were significantly better for the tissue adhesive throughout the evaluation section ( $P < 0.05$ ). More patients in tissue adhesive group had optimum wound evaluation score (WES) than those in the suture group two weeks after surgery. In addition, the tissue adhesive is easy to use with a shorter operation time than suture.

**Conclusion:** TissueAid™ tissue adhesive can alleviate postoperative pain with better aesthetic effect on the scars, and achieve higher patient satisfaction for the incision port caused by the video-assisted thoracoscopic surgeries. TissueAid™ tissue adhesive is safe, effective in video-assisted thoracoscopic surgeries and a sound alternative for wound closure.

**Keywords:** Thoracic surgery; Thoracoscopic; wound healing; tissue adhesive

## 1 INTRODUCTION

Nearly 4500 video-assisted thoracoscopic surgeries (VATS) are performed each year in Taiwan. General anesthesia should be used in video-assisted thoracoscopic surgery, and it is generally completed with 1 to 3 incision ports in axillary line on the 7th or 8th rib to allow the access of thoracoscope. The diameters of the incision ports are around 1 to 2cm. Surgical visual field will usually be affected by small incision in traditional surgery. However, video-assisted thoracoscopic surgery can provide amplification function and good resolution by progressive image system. Various views can be provided by endoscopes of different angles, which is beneficial for operation. In some cases, it can provide better surgery view field than traditional surgery.

These small incision ports in video-assisted thoracoscopic surgeries have significant advantage over traditional surgery with large wound because of the fewer chance for infection and wound dehiscence. They also allow for a faster recovery for the patient and a greater chance for the wound to heal. In addition, smaller incisions also produce fewer scars, less postoperative pain, less complications and reduction of operation time. On the contrary, traditional median laparotomy has incision around 30-40cm; posterior lateral thoracotomy has incision of 25-30cm; rib cutting and median laparotomy has incision around 30-40cm. As a consequence, video-assisted thoracoscopic surgeries came into widespread use and are replacing traditional methods in areas such as primary pneumothorax abnormal alveolar resection, lung tumor diagnosis and treatment, lobectomy for benign pulmonary disease, surgical resection of a pulmonary metastasis, etc. After the surgery, the port-sites are usually closed with sutures.

With the advance of medical technologies and patients' desire for better healthcare, there is need to reduce postoperative pain, scar and complication caused by surgery. Surgical wound closure technologies have evolved from traditional braided suture into absorbable suture, staple, surgical tape and tissue adhesive to reduce complication and scar. 2-octylcyanoacrylate tissue adhesive has been approved by United States Food and Drug Administration (US FDA) for closure of easily approximated edges of surgical and trauma wounds for many years. When compared with several traditional methods (sutures, staples, or adhesive tape) [1-9] for closure of surgical and/or traumatic wounds, 2-octylcyanoacrylate tissue adhesive performed better with several important clinical outcomes. Wound closure with 2-octylcyanoacrylate tissue adhesive can achieve improved aesthetic outcome as opposed to traditional methods. In addition, it is relatively easy to use and requires less physician training [10,23]. In

comparison, the cosmetic appearance of wounds closed by suture usually depends on practitioner's experience. Other than improved aesthetic outcome and less training, 2-octylcyanoacrylate tissue adhesive offers the practitioner a fast and less traumatic closure for appropriately selected wounds and typically do not require the use of local anesthesia. It can close skin incision quickly, accelerate wound healing, increase patient comfort, reduce wound infection risk [22] and reduce pain without the need for suture removal [11-17]. Once it is cured, the tissue adhesive can form a protective layer over the wound that remains in place for 5 to 10 days until the wound heals. As a result, application of 2-octylcyanoacrylate tissue adhesive on the topical skin wound has gained popularity as an alternative method for skin wound closure. It is commonly indicated for the closure of topical skin incisions and trauma-induced lacerations in areas of low skin tension. Many reports of 2-octylcyanoacrylate tissue adhesive focused on applications including, blepharoplasty [8], laparoscopic port-site wounds [18], sternal wounds [19], lacerations at various sites in pediatric [4], surgical incisions of the head and neck [2,21], and more general populations [6].

However, most studies of 2-octylcyanoacrylate tissue adhesive have focused on skin-closure of superficial wounds or wounds with subcutaneous suture. Little research has been published regarding the closure of deep surgical wound without subcutaneous suture. Four randomized controlled trials on 404 patients [18] have been done to evaluate the use of 2-octylcyanoacrylate tissue adhesive and compared with sutures to close laparoscopic port-site wounds without deep suture. Statistically tissue adhesive needs less operation time to close port incision as compared with sutures. Tissue adhesive also has demonstrated port closure capability equal to traditional sutures in terms of wound infection rate, wound dehiscence rate and patient satisfaction. This outcome is significant because the laparoscopic port incisions are usually deep and surrounded by soft tissue and prone to dehiscence.

Similar to laparoscopic port incisions, incisions in thoracic surgeries are also deep. Some researchers have concluded that applying 2-octylcyanoacrylate tissue adhesive to close sternal wounds with deep suture results in superior outcomes in terms of reduced infection rate. This trend is true for both deep surgical site infection (0.6%–0%) and superficial site infection (4.3%–2.1%) [19]. However, little research has been published regarding the closure of deep port incision caused by the video-assisted thoracoscopic surgeries.

A prospective randomized double-blind control trial was done comparing suture to adhesive paper-tape for port incision caused by the video-assisted thoracoscopic

surgeries [20]. There were no significant differences between the adhesive paper-tape and suture in terms of immediate post-operative pain scores, wound cosmeses and wound complications. Compared with adhesive paper-tape, 2-octylcyanoacrylate tissue adhesive is known to have better skin adhesion and better barrier against common bacteria. As a result, there is a need to evaluate the use of 2-octylcyanoacrylate tissue adhesive for epidermal closure of deep surgical incisions caused by the video-assisted thoracoscopic surgeries and compared with conventional suture to assess the possible difference in outcome between these two methods.

TissueAid™ (manufactured by GeneJet Biotech Co., Ltd.) is a new flexible 2-octylcyanoacrylate tissue adhesive used for topical wound closure, with purported advantages over conventional suture for both surgeons and patients in various clinical outcomes such as improved aesthetic outcomes, fast wound healing, improved patient comfort, less infection, less pain and shorter operation time. This study compared results of port closure using TissueAid™ and suture after video-assisted thoracoscopic surgery. Port incisions were randomly selected and closed with either traditional suture method or TissueAid™ without the use of deep suture. Both methods are comparatively studied in the aspects of operation time, complication, infection rate, pain intensity, aesthetic effect, and patient satisfaction. TissueAid™ 's clinical application and its value of being used as wound closure alternative are also evaluated.

## 2. MATERIALS AND METHODS

A total of 30 patients accepted by our department for video-assisted thoracoscopic surgery from March 2015 to August 2015 were recruited for the study. Patient age were 18 years or older. Exclusionary criteria included known sensitivity to cyanoacrylate, pregnant, or with non-healing wound. The subjects were randomly divided into tissue adhesive group of 15 cases treated by tissue adhesive (TissueAid™, 0.8g/unit) and suture group of 15 cases treated by standard 5-0 nylon suture. All surgical preparatory procedures were performed according to standard hospital practice, and the incisions should undergo thorough wound preparation as with traditional repair methods to reduce the risk of infection. They can often be cleansed with an antibacterial compound and flushed with sterile saline solution before closure. The length of the incision and the time needed for wound closure were recorded. For the tissue adhesive group, investigators were instructed to use TissueAid™ to close the wound without using deep suture.

The TissueAid™ is a sterile liquid skin adhesive formulation of high viscosity, high

strength 2-octylcyanoacrylate solution (2-OCA) provided in a sealed Aluminum tube containing 0.8 gram of the adhesive. The single-use Aluminum tube and two applicators are packaged in a sterile Tyvex™ pouch.

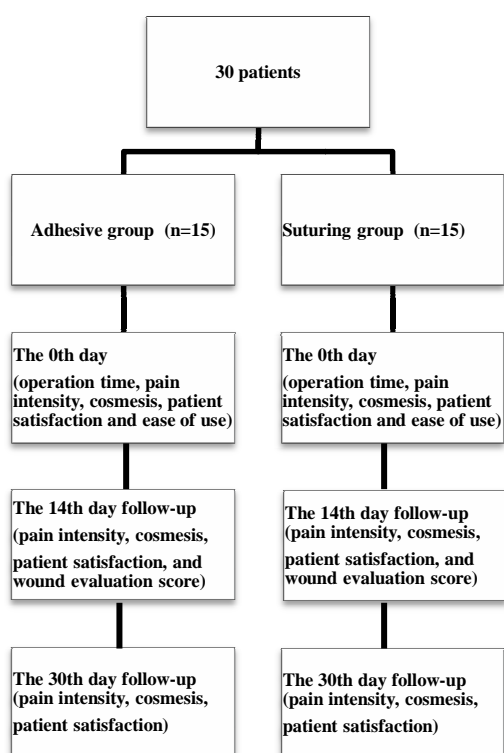
After cleansing, the wound should be positioned so that excess adhesive does not run off into areas not meant to be glued. Excessive moisture on the skin or wound seepage should be patted dried with gauze before closure, because it may prevent good bonding to the epithelial skin layer. For the same reason, good hemostasis should be achieved before using the adhesive. The edges of the wound must be approximated evenly by fingers or by forceps. Once the seal on the Aluminum tube is broken by twisting the applicator clockwise, the adhesive is expressed by gently squeezing the tube, which allows the adhesive to be seen at the applicator tip.

Once the adhesive is at the applicator tip, it is applied to the apposed wound edges with gentle brushing motions. Adhesive should not enter the wound because this may lead to a foreign-body reaction and prevent normal wound healing or cause dehiscence. After the adhesive is applied on the skin, it reacts with the moisture on the skin's surface and begins the solidification process from monomer to polymer. Within minutes it establishes a strong and water repelling polymer bond bridging the approximated skin edges of surgical incisions and close the wounds. During the curing of the adhesive, the wound edges should be held together for at least 30 seconds allowing the adhesive to complete curing before releasing. After the first adhesive layer is cured, more adhesive should be applied gently around the wound to add greater strength to the wound closure. At least two layers should be applied to ensure optimal strength to the wound closure, and the wound should not be touched until the adhesive dries completely. In addition to the wound closure, solidified tissue adhesive film can resist water and form a protective shield on the wound to block bacteria from entering the wound and reduce infection risk. The patient is ambulatory immediate post procedure and may shower normally. After the wound is healed, the adhesive can slough off from the skin in 5-8 days without requiring removal.

For the 15 patients in the suture group, standard hospital practice should be followed to prepare the surgical sites before closing the incision by the suture. The wound should be thoroughly cleaned to reduce the risk of infection. After the wound was closed by 5-0 suture, wounds should be wrapped and covered by ordinary gauze until removal. The patients' follow-up and suture removal was scheduled at clinical department after the operation.

Clinical data from the patients are recorded right after the procedures, on the 14th day and one month post-operation to determine if the new TissueAid™ was equivalent to the suture in various measures of effectiveness. Clinical outcomes to be followed for patients in these two groups are shown in Figure 1; they are: pain intensity, operation time, patient satisfaction, ease of use, wound cosmesis, adequate progress in wound healing and incidence of wound-related complexity such as inflection.

Figure 1, Flow chart for clinical follow up.

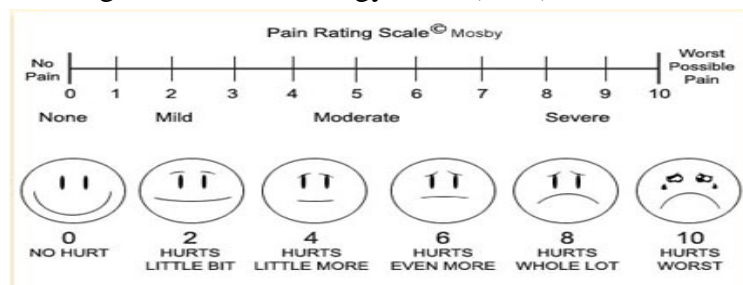


In this study, demographics and wound characteristics were collected on the day of wound closure (day 0) for each subject and were recorded in a case report form. At the time of treatment, investigators recorded the wound length and incision location, treatment method, operation time, ease of use, pain intensity, patient satisfaction, and wound cosmesis. Visual analogy score (VAS) in Figure 2 was used to evaluate patients satisfaction and pain intensity during wound closure process after the operation, wherein 1 represents the lowest score and 10 represents the highest score. Patients evaluated their own pain/satisfaction score and indicated their satisfaction with the use of the products after the operation, on the 14th day and one month later. For the ease of use and wound cosmesis, they were assessed by investigators for their



satisfaction with each use of a device and its effect on wound cosmesis. Both characteristics were also measured using visual analogy score (VAS), wherein 1 represents the worst and 10 represents the best.

Figure 2, Visual analogy score (VAS)



The operation time taken to close each wound was measured with a stop watch. The start time was commenced immediately before each closure operation and finished upon completion of the operation. It included time to achieve hemostasis and, in the case of tissue adhesive, time spent holding the incision edges in apposition until full curing had occurred. Photos of the wound were also taken after the operation, and postoperative day 14 and day 30.

On day 14 after the wound closure, investigators recorded the pain intensity, patient satisfaction, wound evaluation score (WES), wound cosmesis and any wound complications at the time of revisit. Again, visual analogy score (VAS) was used for evaluating patients satisfaction and the pain intensity by the patients, wherein 1 represented the lowest satisfaction/pain and 10 represented the highest satisfaction/pain. Wound evaluation score (WES) and wound cosmesis was evaluated by the investigators. Wound cosmesis was measured using visual analogy score (VASC), and wound evaluation score (WES) was used for evaluating six clinical parameters (as shown in Table 1). Total wound evaluation score (WES) referred to total score of six variables answered by 'yes'. These 6 category scores were added to calculate an overall cosmesis score. Six points represented a perfect result; score less than 6 points represented a less optimal appearance. Expected possible adverse events in this trial included complications typically observed after thoracic surgeries wound closure, including dehiscence, infection, inflammation, erythema, and edema. Infection was considered present if any of the following were observed: redness 3 to 5 mm from the wound, swelling, purulent discharge, pain, increased skin temperature, or fever. Other than that, wounds were also assessed for adequate progress in healing. Healing was considered adequate if wound margins were completely apposed and there was no dehiscence.

Table 1, Wound evaluation score (WES)

<b>Clinical Parameter:</b>	
Step off	0=yes, 1=no
Contour irregularities	0=yes, 1=no
Wound margin separation of >2 mm	0=yes, 1=no
Edge inversion	0=yes, 1=no
Wound complication with infection, dehiscence, inflammation, erythema	1 point for normal healing and 0 point for wound complication with inflammation, erythema, infection, dehiscence
Overall wound appearance	0=bad, 1=acceptable
Total wound evaluation score (WES):	

On post-operative day 30, investigators recorded the following at the time of revisit: pain intensity, patient satisfaction, and wound cosmesis. Again, visual analogy score (VAS) was used for evaluating patients satisfaction and the pain intensity by the patients themselves. Wound cosmesis (VASC) was evaluated by the investigators.

Patients in these two groups were analyzed with multi-factors statistics in the aspects of patients' characteristics (e.g. age, and length of wound) and related factors affecting incision healing and primary clinical outcomes, thereby analyzing whether two groups have statistical difference or not. They were assessed and analyzed using the Student's t test. Comparative results for all analyses were considered significant when  $p < 0.05$ .

### 3. RESULTS

A total of 30 subjects were enrolled in this study. The port incisions of fifteen patients were closed with tissue adhesive, and those of another 15 patients were treated with suture. Both groups had a comparable distribution of age, gender, and wound length. As shown in Table 2, no significant statistical difference was discovered between the demographics and wound lengths of these two groups.

Table 2. Patients demographics

	Tissue Adhesive Group	Suture Group
Gender (Male)	6	9
Gender (Female)	9	6
Age	69.9	60.7
Incision port	32	34
Average wound length (cm)	2.7	2.4

Right after the video assisted thoracoscopic surgery, clinical data such as wound closure operation time, ease of use, patient satisfaction, pain intensity and wound cosmesis were collected from both groups and are shown in Table 3. A high rate of optimal wound cosmesis, defined as a VASC score of 7.5, was obtained and statistically non-inferior to the suture group (VASC=6.5,  $p < 0.001$ ). Representative photos right after the incision closure (Day 0) are shown in Figure 3 for the tissue adhesive group and in Figure 5 for the suture group. The protective film formed on the closed incision in tissue adhesive group was smooth with less marking on the skin.

Figure 3 Adhesive group patient A on the 0th day;

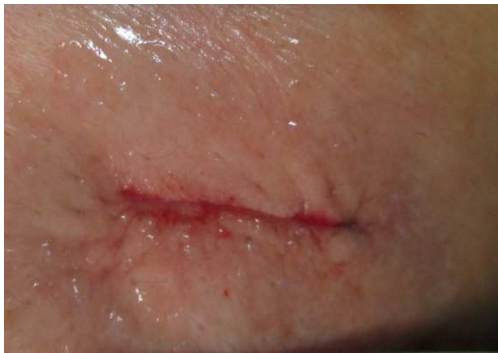

Figure 4 Adhesive group patient A on the 30th day

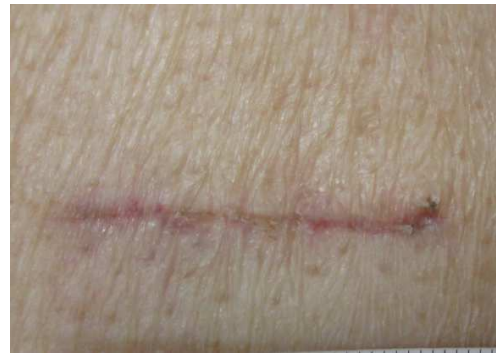

Figure 5 Suturing group patient B on the 0th day;

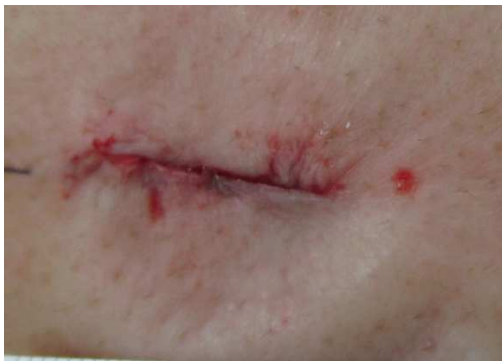
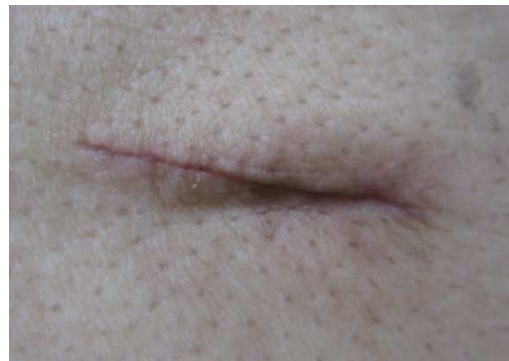
Figure 6 Suturing group patient B on the 30th day



For the evaluation of ease of use, investigators expressed a marked preference for tissue adhesive (defined as a VAS score of 7.1) relative to suture (VAS =6.1, p= 0.04). On the other hand, patients had a high rate of satisfaction of wound treatment and the overall appearance of wounds in both treatment groups. No significant difference in satisfaction in treatment of the incisions was found between the two groups (defined as a VAS score of 8.1 for tissue adhesive vs. 7.9 for suture, P= 0.216). The mean time for wound closure was found to be faster in the tissue adhesive group than in the suture group by approximately 35 seconds. (173.9 seconds for tissue adhesive vs. 209.0 seconds for suture, P= 0.282) In addition, patients from the tissue adhesive group had less pain during the treatment than those in the suture group (defined as a VAS score of 7.3 for tissue adhesive vs. 8.6 for suture, P= 0.018).

Table 3: Clinical data record:

	Tissue Adhesive Group	Suture Group	Difference (95% CI)	p value
Operation time (sec)	173.9	209.0	35.1	0.282
Ease of Use	7.1	6.1	1.0	0.040
Visual analogy score (VAS) for pain intensity ( 0 day )	7.3	8.6	1.33	0.018
Pain intensity (14th day )	4.6	4.7	0.1	0.425
Pain intensity (30th day )	1.9	2.6	0.7	0.004
Visual analogy score (VASC) for Cosmesis (0 day )	7.5	6.5	1.0	<0.001
Cosmesis (14th day )	8.1	6.9	1.2	<0.001
Cosmesis (30th day)	8.4	7.0	1.4	0.005
Visual analogy score (VAS) for Patient satisfaction (0 day )	8.1	7.9	1.3	0.216
Patient satisfaction (14 <sup>th</sup> day)	8.0	7.6	0.4	0.046
Patient satisfaction (30th day )	8.6	8.1	0.5	0.022
<b>Wound Evaluation Score (WES)</b>				
<b>( 14th day )</b>				
Step-off borders	15	15		
Irregular contour	15	15		
Scar wider than 2mm	15	14		

Presence of edge inversion	15	15		
Presence of Wound complication : inflammation, erythema, Infection, dehiscence,	15	15		
Overall cosmesis	15	14		
Sub-optimal wound (% of WES <6)	0(0%)	2(13%)		
Optimal wound (% of WES =6)	15(100%)	13(87%)		
Average Wound Evaluation Score	6.0	5.9	0.1	0.082

On the 14th day after the video assisted thoracoscopic surgery, comparison of postoperative pain, wound evaluation score (WES), patient satisfaction and wound cosmesis (VASC) of the two groups is shown in Table 3. Tissue adhesive group had higher patient satisfaction (8.0 vs. 7.6, P=0.046) and wound cosmesis (8.1 vs. 6.9, P<0.001) than suture group. The differences had statistical significance. The quality of wound healing was also assessed by wound evaluation score (WES), more patients in tissue adhesive group reached optimum score than suture group (100% vs. 87%). No adverse event was reported by the study subjects in either treatment groups during the course of the study. Patients in tissue adhesive group also experienced less pain (4.6 to 4.7, P=0.425) than patients in suture group. However, the differences did not have statistic significance.

Table 3 also shows the comparison of postoperative pain intensity, patient satisfaction and wound cosmesis (VASC) of two groups on the 30th day after video assisted thoracoscopic surgery. Subjects from the tissue adhesive group had higher patient satisfaction (8.6 to 8.1, P=0.022) and better wound cosmesis (8.4 to 7.0, P=0.005) than those from the suture group. Subjects from the tissue adhesive group also experienced less pain (1.9 to 2.6, P= 0.004) than those from the suture group. The differences had statistical significance. Typical photos of treated incision are shown in Figure 4 for tissue adhesive group and Figure 6 for suture group. Incisions treated by tissue adhesive showed less scar than those treated by suture.

Three important clinical results (pain intensity, patient satisfaction and wound cosmesis) at all postoperative time points (on the 0th day, on the 14th day and 1 month later) are illustrated and compared in Figures 7-9. As expected, the wound

cosmesis for both groups improved as healing progress over time during the study period. However, as shown in Figure 7, subjects from the tissue adhesive group realized better wound cosmesis after healing compared with those from the suture group consistently in all three check points. For patient satisfaction, patients in the tissue adhesive group had higher satisfaction with the treatment than those in the suturing group in all three check points (shown in Figure 8). Similar to the wound cosmesis, the patient satisfaction for both groups improved as healing progressed over time.

As shown in Figure 9, patients in both groups experienced less pain as wound healing progress over time. Compared with those in suture group, patients in the tissue adhesive group had less pain during wound healing in all three check points.

Figure 7, Comparison of cosmesis score on three postoperative time points

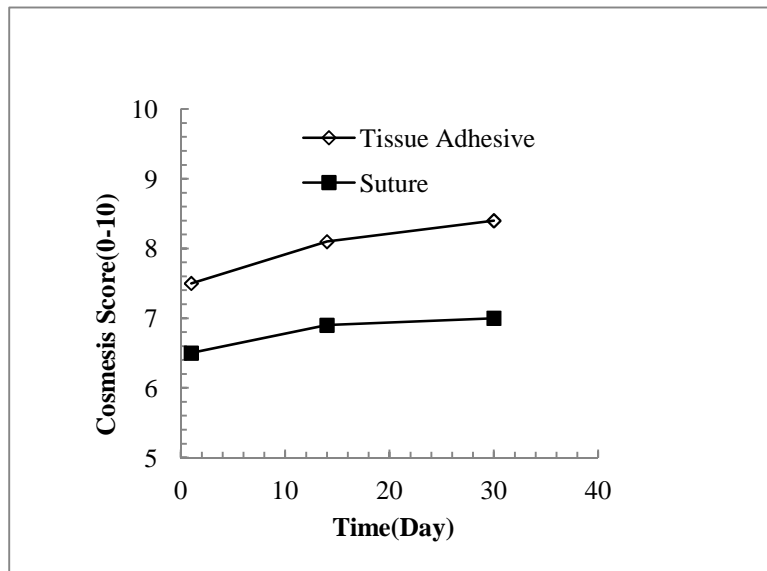


Figure 8 Comparison of patient satisfaction on three postoperative time points

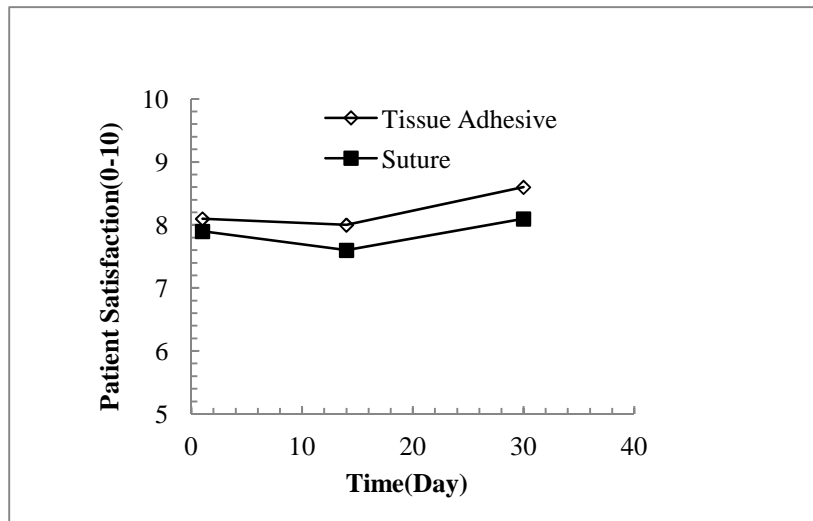
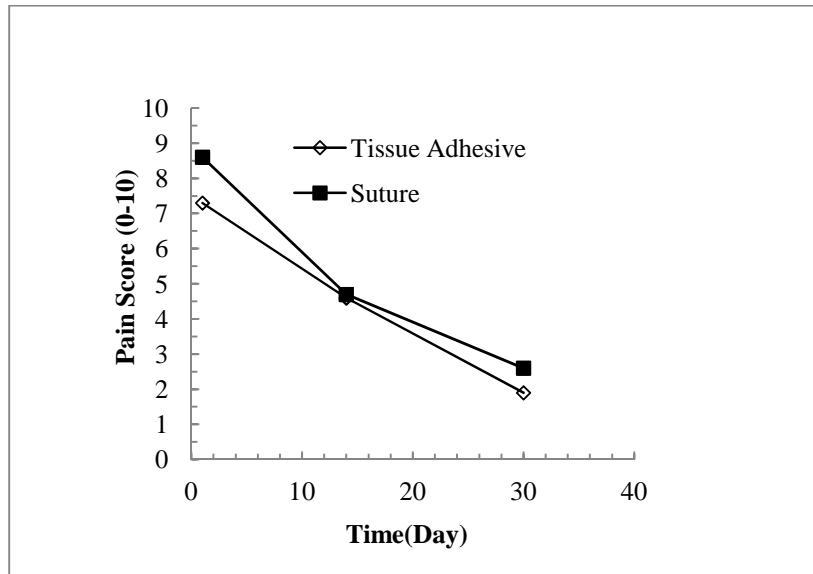


Figure 9 Comparison of pain score on three postoperative time points



#### 4. DISCUSSION

Although sutures are still considered the most commonly used technique for incision closure, many patients prefer topical tissue adhesive when compared with sutures and staples [10,21]. TissueAid™ tissue adhesive is a novel skin adhesive which is mainly composed of flexible 2-octylcyanoacrylate monomer and D&C #2 purple dye. The benefits of using 2-octylcyanoacrylate tissue adhesive over staples and sutures are the following: ease of use, improved wound cosmesis, rapid hemostasis and wound closure, shortened operation time, no pain can be felt during wound closure process, no anesthetic is needed, and no follow-up visit is required for removal.

TissueAid™ tissue adhesive is especially suitable for children and facial wounds

because wounds treated by tissue adhesive can heal linearly without the excess stresses that comes from the suture and staple. As a result, excessive hypertrophic scar caused by suture compression on incision edge can be avoided with better wound cosmesis (VASC). In addition, stimulation from the suture, staple or other foreign matters on the skin is also avoided when the wound is treated by the tissue adhesive. Therefore, less inflammation and scars was induced after the wound is healed. In addition, TissueAid™ tissue adhesive can form a protective antibacterial film on the wound after it is cured. Because of this strong and waterproof film, the infection risk is reduced; and there is no bathing restriction. With the reduced infection risk, the wound can heal properly with fewer scars. Similar to the results from other randomized studies for wound cosmesis [24,25], TissueAid™ tissue adhesive have been shown to be statistically better than sutures regarding wound cosmesis with a comparable complication rate at the 14th days and 30th days follow-up.

Cosmetic outcome is a significant end point of wound repair to patients [16]. Other than wound cosmesis score (VASC), the quality of wound healing was also assessed by wound evaluation score (WES). An incision was deemed to have achieved an optimal cosmetic outcome if it received a WES score of 6. In this study, scores of WES for both treatment groups were high (>80%). However, more patients achieved a 6 score of WES in the tissue adhesive group (100%) than those in suture group (83%) at the 14th days follow-up; a result that was also apparent in the other assessment of wound cosmesis by VASC. Wound infection rates were found to be low for both treatment groups. Comparison of infection rates after topical wound closure has been previously studied with no significant difference found between tissue adhesives and sutures [27]. In other studies [26], evidence of low infection rates after the use of cyanoacrylates has been documented, and this may be due to the barrier properties provided by the cured adhesive in preventing microorganism infection of the wound site.

Other than the infection, no dehiscence was observed in both study groups and mirrored the results from rate of infection. This low dehiscence rate for each treatment group was consistent with results from other studies [26, 27]. There were no deaths or unanticipated adverse effects among either treatment group, with most events reported being mild or in low severity. The only significant differences were that patients in the suture group had more scar wider than 2mm and less cosmesis score than patients in the tissue adhesive group.

One of the main finding of this study is that the TissueAid™ tissue adhesive is



equivalent to traditional suture for incision closure of video assisted thoracoscopic surgery based on adequacy of healing. Although 2-octylcyanoacrylate tissue adhesive had been found to be as effective as traditional skin closure devices for closing superficial wounds [1-9], we verified the ability of TissueAid™ to withstand the potentially greater cutaneous stresses of deep wounds without using subdermal suturing to minimize such stresses. Equivalence in healing progress was found for tissue adhesive group versus suture group.

Investigators were very satisfied with the results across both treatment groups. However, a higher score for ease of use has been reported in tissue adhesive group than in suture group by the investigators. This result is also consistent with the findings in other studies [27]. Other than the positive feedback from the clinicians, patient satisfaction is very important to the quality of wound care; and patients from either group in this study were very satisfied with the treatments. This satisfaction may include comfort of treatment, need for dressing change, hygiene and bathing concerns, and wound cosmesis results. The VAS score of patient satisfaction in the tissue adhesive group was found to be statistically higher than those in the suture group at the 14th days, 30th days follow-up, which is also consistent with previous reports [28].

For the pain intensity, patients in the tissue adhesive group experienced reduced pain during the wound healing period. This trend is apparent from the post-operative follow-up at 0 day, 14th days, and 30th days, and is shown in Figure 9. Compared with patients in suture group, those in the tissue adhesive group had less pain during wound healing in all three check points. In addition, the study results show that tissue adhesive needs shorter operation time than traditional suture. However, this difference did not reach statistical significance. This is possibly due to the size of subject—calculated for determination of equivalence—did not provide sufficient statistical power for the comparison.

## 5. CONCLUSION

The results of this randomized clinical trial provide valid scientific evidence that TissueAid™ provides adequate closure for the incisions caused by the video assisted thoracoscopic surgery without the use of subdermal sutures. TissueAid™ is equivalent to the commercially available device (suture) in various clinical measures of effectiveness at days 0, 14, and 30 post-operation. According to the investigators, the TissueAid™ is easy to use and feasible for incisions closure. Tissue adhesive realizes

considerable better wound cosmesis (VASC) after healing with higher patient satisfaction. Patients in the tissue adhesive group are more satisfied with their wound healing compared with those in the suture group, and this is consistent through the study period. Tissue adhesive is also substantially better than suture regarding reduced pain intensity. More patients in the tissue adhesive group obtained optimum wound evaluation score (WES) (100% vs. 87%) than the suture group. This is also consistent with the results from the wound cosmesis score (VASC) executed in this study. However, no significant difference was observed between tissue adhesive and suture in the aspects of operation time. There was no severe incidence of wound-related complexity such as: inflection, inflammation, erythema, and dehiscence in either group.

## 5. REFERENCE

1. Hollander JE, Singer AJ., Laceration management. *Ann Emerg Med* 1999;34:356–67.
2. Maw JL, Quinn JV, Wells GA, et al., A prospective comparison of octylcyanoacrylate tissue adhesive and sutures for the closure of head and neck incisions. *J Otolaryngol* 1997;26:26–30.
3. Quinn J, Wells G, Sutcliffe T, et al., A randomized trial comparing octylcyanoacrylate tissue adhesive and sutures in the management of lacerations. *JAMA* 1997;277:1527–30.
4. Bruns TB, Robinson BS, Smith RJ, et al. A new tissue adhesive for laceration repair in children. *J Pediatr* 1998;132:1067–70.
5. Quinn J, Wells G, Sutcliffe T, et al. Tissue adhesive versus suture wound repair at 1 year: randomized clinical trial correlating early, 3-month, and 1-year cosmetic outcome. *Ann Emerg Med* 1998;1998: 645–9.
6. Singer AJ, Hollander JE, Valentine SM, et al. Prospective, randomized controlled trial of tissue adhesive (2-octylcyanoacrylate) vs standard wound closure techniques for laceration repair. *Acad Emerg Med* 1998;5:94–9.
7. Toriumi DM, O’Grady K, Desai D, Bagal A. Use of octyl-2-cyanoacrylate for skin closure in facial plastic surgery. *Plast Reconstr Surg* 1998;102:2209–19.
8. Greene D, Koch RJ, Goode RL. Efficacy of octyl-2-cyanoacrylate tissue glue in blepharoplasty. A prospective controlled study of wound-healing characteristics. *Arch Facial Plast Surg* 1999;1:292–6.
9. Singer AJ, Quinn JV, Clark RE, Hollander JE. Closure of lacerations and incisions with octylcyanoacrylate: A multicenter randomized trial. *Surgery* 2002;131:270–6.

10. Roberts AC. The tissue adhesive indermil and its use in surgery. *Acta Chir Plast.* 1998;40:22–25.
11. Farion K, Osmond MH, Hartling L, et al. Tissue adhesives for traumatic lacerations in children and adults. *Cochrane Database Syst Rev* 2002;3: CD003326.
12. Quinn J, Wells G, Sutcliffe T, et al. Tissue adhesive versus suture wound repair at 1 year: randomized clinical trial correlating early, 3-month, and 1-year cosmetic outcome. *Ann Emerg Med* 1998;32: 645-9.
13. Hollander JE, Valentine SM, McCuskey CF, Turque T, Singer AJ. Long-term evaluation of cosmetic appearance of repaired lacerations: validation of telephone assessment. The Stony Brook Wound Registry Study Group. *Ann Emerg Med* 1998;31: 92-8.
14. Bernard L, Doyle J, Friedlander SF, Eichenfield LF, Gibbs NF, Cunningham BB. A prospective comparison of octyl cyanoacrylate tissue adhesive (Dermabond) and suture for the closure of excisional wounds in children and adolescents. *Arch Dermatol* 2001;137: 1177-80.
15. Quinn J, Wells G, Sutcliffe T, et al. A randomized trial comparing octylcyanoacrylate tissue adhesive and sutures in management of lacerations *JAMA*, 1997, 277: 1527~1530.
16. Quinn J, Wells G, Sutcliffe T, et al. Tissue adhesive versus suture wound repair at 1 year: randomized clinical trial correlating early, 3-month, and 1-year cosmetic outcome. *Ann Emerg Med*, 1998, 32(6): 645-649.
17. Quinn J, et al. A randomized trial comparing octylcyanoacrylate tissue adhesive and sutures in the management of lacerations *JAMA*, 1997: 227(19): 1527—1530, 8.
18. Sajid MS, Siddiqui MR, Khan MA, Baig MK. Meta-analysis of skin adhesives versus sutures in closure of laparoscopic port-site wounds. *Surg Endosc.* 2009 Jun; 23(6):1191-7.
19. Chambers A, Scarcib M, Is skin closure with cyanoacrylate glue effective for the prevention of sternal wound infections? *Oxford Journals Medicine & Health, Interactive CardioVasc Thoracic Surgery*, Volume 10, Issue 5, pp. 793-796
20. Luckraz H, Rammohan KS, Phillips M, O'Keefe PA, Is adhesive paper-tape closure of video assisted thoracoscopic port-sites safe? *European journal of Cardio-thoracic Surgery*, 32:1 2007 Jul pg 167-8
21. Laccourreya O, Cauchois R, Sharkawy EL L. Octylcyanoacrylate (Dermabond) for skin closure at the time of head and neck surgery: a longitudinal prospective study. *Ann Chir.* 2005;130:624–630.

22. Bhende S, Rothenburger S, Spangler DJ, et al, In vitro assessment of microbial barrier properties of Dermabond topical skin adhesive, *Surg Infect(Larchmt)*, 2002, 3(3): 251-257 .
23. Trott AT. Cyanoacrylate tissue adhesives. An advance in wound care. *JAMA* 1997;277:1559–60.
24. Sebesta MJ, Bishoff JT. Octylcyanoacrylate skin closure in laparoscopy. *JLS*. 2004;8:9–14.
25. Dowson CC, Gilliam AD, Speake WJ, Lobo DN, Beckingham IJ. A prospective, randomized controlled trial comparing n-butyl cyanoacrylate tissue adhesive (LiquiBand) with sutures for skin closure after laparoscopic general surgical procedures. *Surg Laparosc Endosc Percutan Tech*. 2006;16:146–150.
26. Coulthard P, Esposito M, Worthington HV, van der Elst M, van Waas OJF, Darcey J. Tissue adhesives for closure of surgical incisions. *Cochrane Database Syst Rev*. 2010;5:CD004287.
27. Kent A, Liversedge N, Dobbins B, McWhinnie D, and Jan H, A Prospective, Randomized, Controlled, Double-Masked, Multi-Center Clinical Trial of Medical Adhesives for the Closure of Laparoscopic Incisions, *Journal of Minimally Invasive Gynecology*, 2014;21, 252–258
28. Wong EML, Rainer TH, Ng YC, Chan MS, Lopez V, Cost-effectiveness of Dermabond versus sutures for lacerated wound closure: a randomised controlled trial, *Hong Kong Med J*. 2011;17(Suppl 6):S4-8